

# Detection of Hard Exudates, Soft Exudates, Red Spots and Hemorrhages

<sup>[1]</sup> S.Saranya devi, <sup>[2]</sup> P.Anuja, <sup>[3]</sup> Bhagyalakshmi.K.M, <sup>[4]</sup> Jinchu.J

<sup>[1]</sup>. Assistant professor, <sup>[2][3][4]</sup> Final year BE

<sup>[1][2][3][4]</sup> Department of Biomedical Engineering Dr.NGP Institute of technology, Coimbatore

---

**Abstract:** The most complex system in human body is eye. Nowadays there is increase in vision loss patients mainly due to retinal diseases. Some diseases cannot be identified early unless it affects the vision as it has no symptoms. But it can be identified by some clinical signs in the retina which cannot be viewed through naked eye but through fundus photography. Traditionally, retinal diseases are diagnosed by manual observations of fundus images and it is a time consuming process. So an automatic algorithm is need to be develop to detect and classify various clinical signs. Some of the clinical signs of retinal diseases are hard exudates, soft exudates, red spots and haemorrhage. We used MATLAB software to develop an algorithm. Various techniques have been proposed to detect these signs but the efficiency is less and there is a chance of mismatching. Hence we proposed a new technique known as skin locus model which is used only for face detection till now. In this technique pixels between the images are compared and based on certain threshold the various clinical signs are detected ad classified. We used DRIVE database, an open source database images, which has been acquired from the fundus photography. Our proposed algorithm reduces man power, time consumption and also help the retinal diseased patients by preventing or delaying the vision loss. It also avoid mismatching of clinical signs.

---

## I. INTRODUCTION

The eye is a hollow, spherical organ about 2.5cm in diameter. It has a wall composed of three layers, and its interior spaces are filled with fluids that support the walls and maintain the shape of the eye .The eyes are so important that four-fifth of all of the information the brain receives, come from the eyes. The vision is captured and sensed by the human body using the eye. The cornea is a transparent medium situated in the front of the eye covering the iris, pupil and anterior chamber that helps to focus incoming light with a water content of 78%. The cornea is supplied with oxygen and nutrients through tear-fluid and not through blood vessels. Therefore, there are no blood vessels in it. The function of the cornea is to refract and transmit light. The iris is a thin, pigmented, circular structure in the eye which regulates the amount of light that enters the eye. The quantity of light entering the eye is controlled by iris. The function of the iris is to control the size of the pupil by adjusting it to the intensity of the lighting conditions. By expanding the size of the pupil, more light can then enter. The pupil is a hole in the center of the iris. The size of the pupil determines the amount of light that enters the eye. The pupil size is controlled by the dilator and sphincter muscles of the iris. It appears black because most of the light entering the pupil is absorbed by the tissues inside the eye. The lens is a transparent, biconvex structure in the eye that, along with the cornea, helps to refract light to be focused on the retina. The sclera is the white opaque tissue that acts as the eye protective outer coat.

Six tiny muscles connect to it around the eye and control the eye's movements. The optic nerve is attached to the sclera at the very back of the eye. The optic disc, also known as the optic nerve head or the blind spot. The optic disc is where the optic nerve attaches to the eye. There are no light sensitive rods or cones to respond to a light stimulus at this point. This causes a break in the visual field called "the blind spot" or the "physiological blind spot. The retina is a thin layer of neural cells that lines in the inner back of the eye. It is light sensitive and absorbs light. The image signals are received and send to the brain. The retina contains two kinds of light receptors; rods and cones. The rods absorb light in black and white. The rods are responsible for night vision. The cones are color sensitive and absorb stronger light. The cones are responsible for color vision. The retina of the eye sensory tissue that lines a multilayered is behind millions of photoreceptors that capture light rays and convert electrical impulses to travel with these impulses from the optic nerve to the brain where they are turned into images of photoreceptors in the retina. Around 120 million rods are more sensitive and responsible for vision at low light levels and cones are capable of color vision.

Nowadays there is increase in number of vision loss patients mainly due to retinal diseases. The main clinical signs of retinal diseases are hard exudates, soft exudates, hemorrhage and red spots. Some of the retinal diseases can be detected early by their symptoms and others are detected only in their advanced stage. Diabetic retinopathy is one of the disease which is identified in the

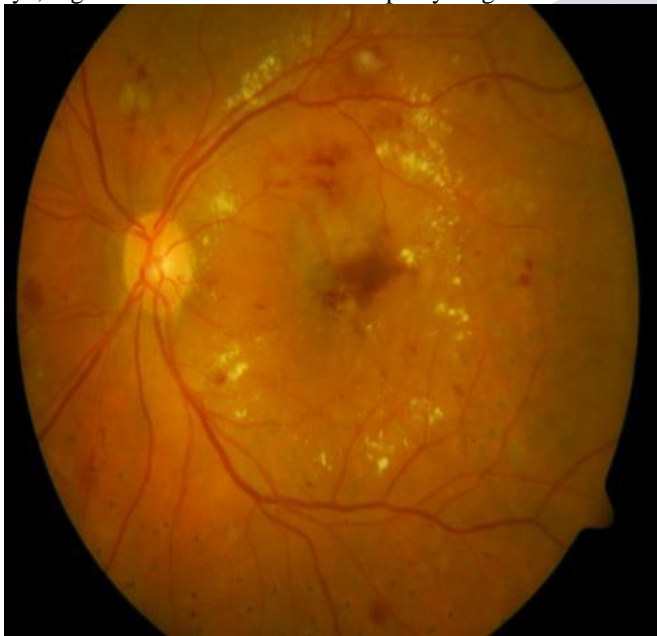advanced stage. These clinical signs are not be identified by the naked eyes. So an algorithm is required for the automatic detection of these signs. The MATLAB software is used to develop the algorithm. By this, man power is reduced along with the time consumption. The scope of this project involves using various MATLAB imaging techniques to obtain the desire result. By the proposed imaging techniques mismatching of normal and abnormal images are reduced.

## II. CLINICAL SIGNS AND DETECTION METHODS

### A. Exudates

Hard exudates often described as hard exudates, these are deposits of extravasated plasma proteins, especially lipoproteins. They leak into retinal tissue with serum, and are left behind as oedema fluid is absorbed. Eventually exudates are cleared from the retina by macrophages. They appear as yellow-white dots within the retina. The yellow deposits may be seen as either individual spots or clusters usually near optic disc.

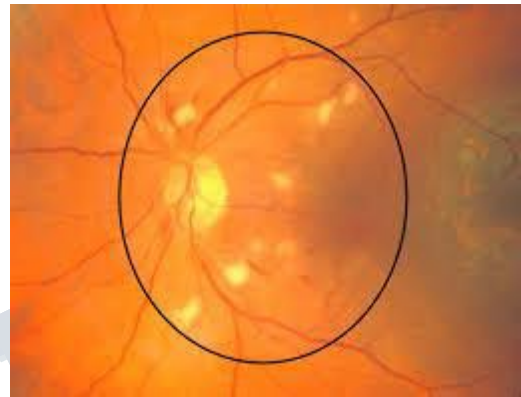
Sometimes the exudates may be formed on macula or fovea, as a result, there will be sudden loss of vision in that eye, regardless of the diabetic retinopathy stages.



### B. Soft exudates

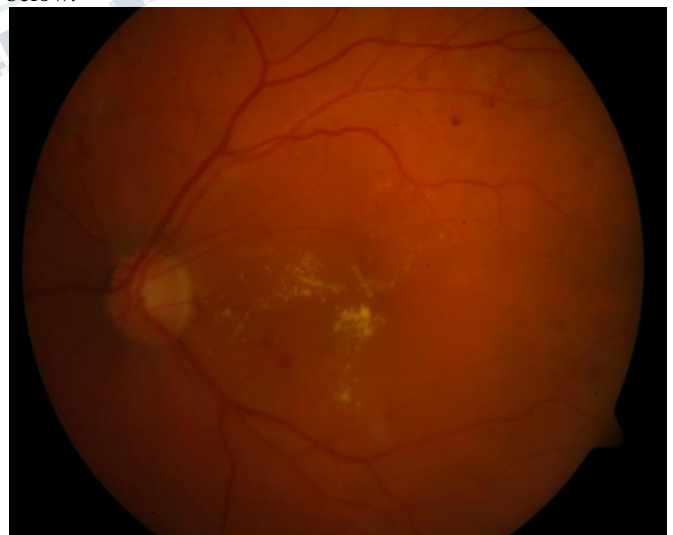Cotton wool spots are an abnormal finding on fundoscopic exam of the retina of the eye. They appear as fluffy white patches on the retina. They are caused by damage to nerve fibres and are a result of accumulations of axoplasmic material within the nerve fibre layer. There is reduced axonal transport (and hence backlog and accumulation of intracellular products) within the nerves because of the ischemia. This then causes the nerve fibres to be damaged by swelling in the surface layer of the retina. A

1981 analysis concluded that "in most instances, cotton-wool spots do not represent the whole area of ischaemic inner retina but merely reflect the obstruction of axoplasmic flow in axons crossing into much larger ischaemic areas". Associated findings include microvascular infarcts and haemorrhages. The appearance of cotton wool spots may decrease over time. Abundant cotton wool spots are seen in malignant hypertension.



### C. Red spots

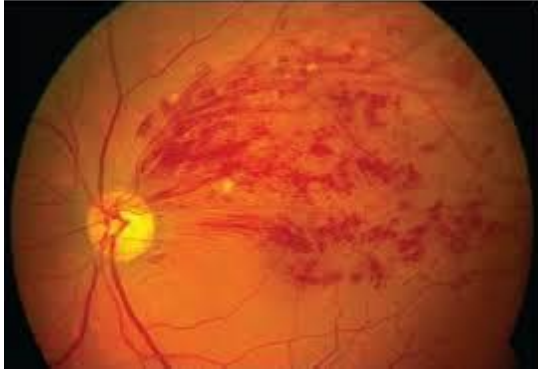The appearance of a small circular choroid shape as seen through the fovea centralis. Its appearance is due to a relative transparency of the macula; storage disorders cause the accumulation of storage material within the cell layers of the retina, however, the macula, which is relatively devoid of cellular layers, does not build up this material, and thus allows the eye to see through the macula to the red choroid below.



### D. Haemorrhage

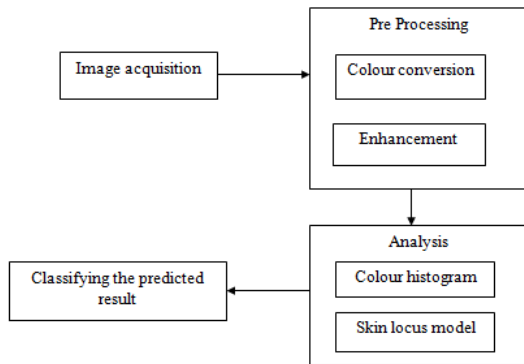
Retinal hemorrhage is a disorder of the eye in which bleeding occurs into the light sensitive tissue on the back wall of the eye. A retinal hemorrhage can be caused by hypertension, retinal vein occlusion (a blockage of a retinal

vein), or diabetes mellitus (which causes small fragile blood vessels to form, which are easily damaged). Retinal hemorrhages can also occur due to shaking, particularly in young infants (shaken baby syndrome) or from severe blows to the head.



**E. Image Processing**

Retinal disease may cause damage to blood vessel. The image will undergo a standard method of applying image processing which include image acquisition, pre-processing, Skin locus model and Color histogram for classification of the retinal images into category of normal and abnormal. The Overall classification rate of the proposed system will give the better efficiency and accuracy of identifying the disease with respect to existing systems.



There is a dataset consists four different types of retinopathy (Hard exudates, soft exudates, hemorrhages and red small dots). Among those images select anyone of the image to classify.

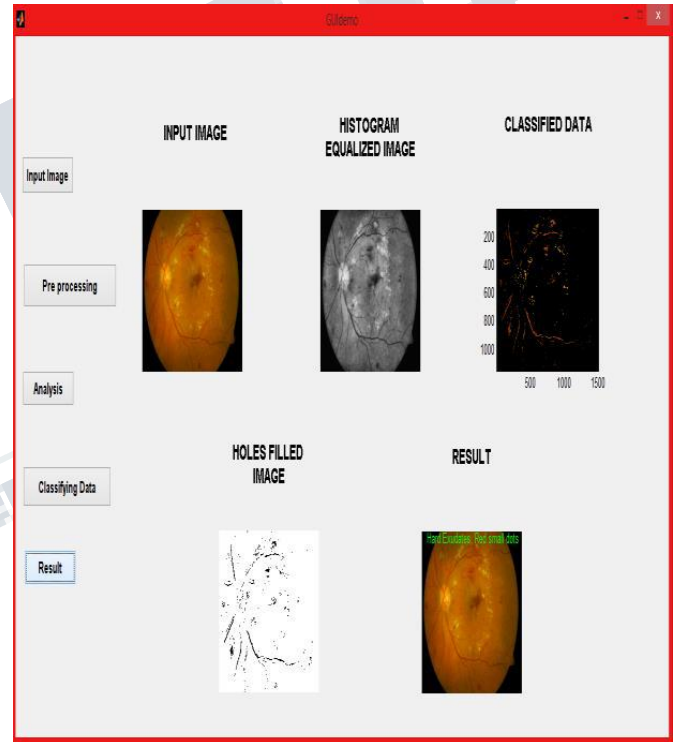
**Preprocessing:** Preprocessing steps are performed to improve the quality of the fundus retinal images. In preprocessing, two plane conversions is done by converting into gray format if the taken image as supposed to be three plane image. Histogram equalization is a technique for adjusting image intensities to enhance contrast. Because of

this enhancement visual quality will be little bit better and easy to analysis. The values will be varied up to 256.

**Algorithm Implementation:** In general, to detect and classify anything in image processing some features such as area, centroid, mean values are used. In this pixel area is used. By calculating this and comparing with the ground truth image the desired result is obtained. This technique is known as skin locus model.

**III.RESULT**

Graphical User Interface or GUI is also developed. It is a type of user interface that allows users to interact with the program by clicking or typing. It allows the image features to display for both normal and abnormal classification.



When input image pushbutton is pressed it automatically take us to the folder with database images. Then any input image is selected which will display in its respective box. The preprocessing button performs histogram equalization. The images are evaluated by clicking analysis button. Then the classifying data push button is pressed to display its respective results. Finally by clicking result button the selected image is displayed along with the respective result.

#### IV. CONCLUSION

Thus a novel algorithm has been developed using MATLAB software to detect various clinical signs. This algorithm reduces man power and time consumption. We validated this only by visual response. Presently we are calculating theoretically.

#### REFERENCES

1. Sharib Ali, Kedir M. Adal, Desire Sidibe, Thomas P. Karnowski, Edward Chaum, M.D. and Fabrice Meriaudeau, "Exudate Segmentation on Retinal Atlas Space", *International Symposium on Image and Signal Processing and Analysis, Trieste, Italy*, no.5, pp. 693-697, Sep. 2013.
2. Diptoneel Kayal and Sreeparna Banerjee, "Detection of hard exudates using simulated annealing based thresholding mechanism in digital retinal fundus image", *David C. Wyld (Eds) : ICCSEA*, pp. 119-124, 2013.
3. Carla Agurto, Honggang Yu, Victor Murray, Marios S. Pattichis, Simon Barriga, Peter Soliz, "Detection of Hard Exudates and Red Lesions in the Macula Using a Multiscale Approach", *Image Analysis and Interpretation (SSIAI), IEEE Southwest Symposium*, pp.13-16, 2012
4. Ivo Soares<sup>1</sup>, Miguel Castelo-Branco<sup>1</sup>, Antonio M.G. Pinheiro, "Curvature Detection and Segmentation of Retinal Exudates", *Biomedical Imaging (ISBI), 9th IEEE International Symposium*, pp. 1719-1722, 2012.
5. Clara I. Sanchez<sup>a,b</sup>, Maria Garcia<sup>a</sup>, Agustin Mayoc, Maria I. Lopez<sup>b</sup>, Roberto Hornero<sup>a</sup>, "Retinal image analysis based on mixture models to detect hard exudates". *Medical Image Analysis*, pp. 650-658, 2009.