

# Follicle Segmentation of Ultrasound Images by Enhancement and Sub-Image Classification

<sup>[1]</sup>V. Anitha, <sup>[2]</sup>M. Shameena Banu, <sup>[3]</sup>S. Srilekha

<sup>[1]</sup> <sup>[2]</sup> <sup>[3]</sup>Research students, Department of Biomedical Engineering,  
GKM College of Engineering and Technology, Chennai. Tamilnadu

<sup>[1]</sup>anithaanju1105@gmail.com, <sup>[2]</sup>shameenashamee285@gmail.com, <sup>[3]</sup>srilekhanandy@gmail.com

---

**Abstract:---** Polycystic Ovary Syndrome is a problem in which a woman's hormones are out of balance. The cysts are not harmful but leads to hormone imbalances. Early diagnosis and treatment can help to control the symptoms and prevent long term problems. This paper presents a novel in three stage follicle detection and segmentation using Anisotropic diffusion algorithm of Ultrasound images. This system has pre-processing, enhancement, morphological operations and follicle extraction. The proposed system performs a follicle extraction, using Modified Contrast Limited Adaptive Histogram Equalization [MCLAHE] transform algorithm and Weighted Median Filter Algorithm. The performance analysis is performed using confusion matrix. In this Result we focus mainly on MCLAHE based segmentation, this approach is analyzed by Confusion Matrix Performance. Our future work is package development and GUI development using MATLAB Package Tools.

**Keywords:—**Image processing, MCLAHE, Polycystic Ovary Syndrome, Weighted Median Filter

---

## I. INTRODUCTION

**PCOS** is the most common endocrine disorder among women between the ages of 18 and 44. It affects approximately 2% to 20% of this age group depending on how it is defined. It is one of the leading causes of poor fertility. Women with PCOS may have enlarged ovaries that contain small collections of fluid called follicles located in each ovary as seen during an ultrasound exam. The syndrome is characterized by the classical traits of menstrual irregularity, hyperandrogenism and polycystic ovaries on ultrasound. A significant proportion of these women suffer from cardiovascular disease (CVD) and Type II diabetes mellitus (DM2) in the long term. Moreover, most of these women will suffer from anovulatory infertility. Early detection and treatment significantly improve the chances of conception as well as offer better long term health prognosis especially as often the disease is manifested early in puberty and worsen with the age and lack of treatment.

### **Long term metabolic complication of PCOS—Prediabetes, type 2 diabetes and cardiovascular disease**

In PCOS, prospective trials have shown a 35% prevalence of prediabetes, a 10% prevalence of DM2, a 5-10 fold risk of progression from prediabetes to DM2 and a 4-7 fold higher risk of DM2. CVD appears increased in PCOS despite inadequate long-term studies to appropriately address this question. It is proposed in the international Androgen

Excess and PCOS Society (AE-PCOS) consensus statement that those with PCOS and obesity, cigarette smoking, dyslipidemia, hypertension, impaired glucose tolerance, and subclinical vascular disease are at increased relative CVD risk, and those with metabolic syndrome and/or DM2 are at even greater relative risk. In the general population IR is a predictor of CVD.

During ultrasonographic evaluation of the ovary in a suspected PCOS patient, overlapping of the follicles as well as noise of the equipment may make diagnosis of polycystic ovaries time consuming and tedious. Moreover, results would vary considerably from one operator to another as it is largely an experience dependent procedure. Thus we tried to develop a model for automated detection of the polycystic ovary on ultrasound.

The Rotterdam consensus is currently the most important criteria for diagnosing this condition. According to it a patient may be diagnosed as suffering from PCOS as long as she has any two of the following three criteria:

- (i) Chronic Anovulation- clinically manifested as irregular/ infrequent menstrual cycles,
- (ii) Hyperandrogenism- clinically evident as acne, hirsutism and elevated serum enzymes,
- (iii) PCOS ovaries on ultrasound. PCOS ovaries have a characteristic appearance on ultrasound imaging showing the presence of multiple cysts, typically 12 or more

measuring between 2-9 mm in a peripheral distribution along the border of the ovary, classically described as the “necklace formation”. Often they may be distributed throughout the ovary as well. It is thought that these cysts are developed due to the hormonal imbalance which characterize these patients is ambiguous and not yet fully clear. Moreover, the ovarian volume in such patients is typically increased over 10 cm<sup>3</sup>.

**Rotterdam diagnostic criteria requires two of:**

1. Oligo- or anovulation;
2. Clinical and/or biochemical signs of hyperandrogenism;
3. Polycystic ovaries; and exclusion of other aetiologies such as congenital adrenal hyperplasia, androgen-secreting tumours and Cushing’s syndrome.

**Hyperandrogenism** is diagnosed based on two of three of menstrual disturbance and clinical/biochemical manifestations of hyperandrogenism and polycystic ovaries on ultrasound after exclusion of other conditions such as thyroid dysfunction, congenital adrenal hyperplasia, hyperprolactinaemia, androgen-secreting tumours and Cushing’s syndrome. Diagnosis of PCOS is challenging as the presenting symptoms and signs are heterogenous depending on populations studied, degree of obesity and life stage of the women affected and indeed clinical features may vary over time within an individual woman.

In this paper firstly patients ultrasound image was cropped and then converted into a gray scale image. After converting into a gray scale the RGB layers are Extracted. After extracting using Modified Contrast Limited Adaptive Histogram Equalization [MCLAHE] the input image is Enhanced. Due to speckle noise in Ultrasound image it is very difficult to trace the boundaries. Using Weighted Median Filter the Follicle region is extracted. The PSNR is applied and then the Follicle regions are segmented. The cyst and Follicle regions are Segmented. Binary process is carried out to obtain the Prewitt operator image and Canny operator image. Canny edge process is applied to identify the Follicle region. After processing all the images using image processing technique a Confusion Plot is obtained. With the help of the Confusion plot and manual result, PCOS can be diagnosed and cured at the Initial stage.

## II. MATERIALS AND METHODOLOGY

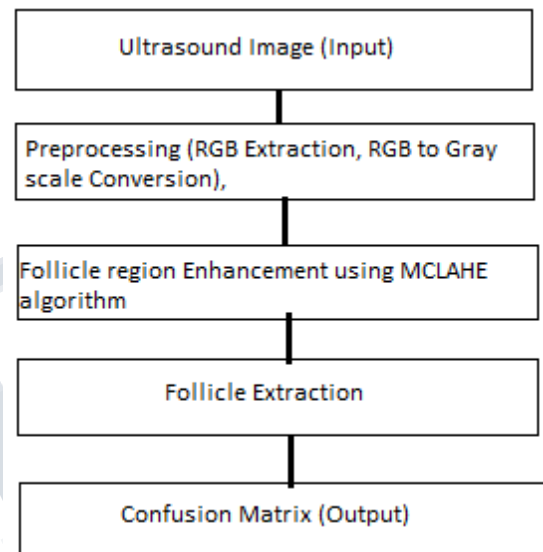
### A. Data Collection

This study was conducted at Apollo Hospital. Patient in the age group 40 – 45 years suffering from Infertility /PCOS were included. The Ultrasound was Performed by the

Ultrasonographer and later verified by the Gynaecologist. The patient was also suffering from DM2 and obesity. The patients with hyperthyroidism and Cushing Syndrome were excluded from the analysis. The imaging data was processed as per the methodology.

### B. Methodology

The figure 1 shows the block diagram of the proposed methodology.



**Figure 1: Schematic diagram of Follicle extraction**

## III. HISTOGRAM EQUALIZATION

Histogram equalization is one of the well-known enhancement techniques. In histogram equalization, the dynamic range and contrast of an image is modified by altering the image such that its intensity histogram has a desired shape. This is achieved by using cumulative distribution function as the mapping function. The intensity levels are changed such that the peaks of the histogram are stretched and the troughs are compressed. If a digital image has  $N$  pixels distributed in  $L$  discrete intensity levels and  $n_k$  is the number of pixels with intensity level  $ik$  and then the probability density function (PDF) of the image is given by Equation (1). The cumulative density function is defined in Equation (2).

$$f_i(i_k) = \frac{n_k}{N} \quad (1)$$

$$F_k(i_k) = \sum_{j=0}^k f_i(i_j) \quad (2)$$

Though this method is simple, it fails in Follicle Segmentation image since the gray values are physically far apart from each other in the image. Due to this reason histogram equalization gives very poor result for Follicle Segmentation Images.

#### IV. MODIFIED CONTRAST LIMITED ADAPTIVE HISTOGRAM EQUALIZATION [MCLAHE]

Modified Contrast-Limited Adaptive Histogram Equalization is a method that has shown itself to be useful in assigning displayed intensity levels in medical images. The method is designed to allow the observer to easily see, in a single image, all contrast of clinical or research interest. The method examines a histogram of intensities in a contextual region centered at each pixel and sets the displayed intensity at the pixel as the rank of that pixel's intensity in its histogram. That histogram is a modified form of the ordinary histogram in which the contrast enhancement induced by the method at each intensity level is limited to a use-selectable maximum. In various observer studies MCLAHE has been shown to allow the detection of contrast changes as effectively as interactive intensity windowing.

In Modified Contrast Limited Adaptive Histogram Equalization the histogram is cut at some threshold and then equalization is applied. CLAHE is an adaptive contrast histogram equalization method, where the contrast of an image is enhanced by applying CLHE on small data regions called tiles rather than the entire image. The resulting neighboring tiles are then stitched back seamlessly using bilinear interpolation. The contrast in the homogeneous region can be limited so that noise amplification can be avoided. In CLAHE the output value for a pixel is its rank in a histogram of pixel intensity values in the contextual region; this is the same as counting the number of pixels in the contextual region whose intensities are less than the affected pixel.

#### V. SEGMENTATION

In an ultrasound image many undesired structures can be found like blood vessels, nerve fibers, lymphatic glands and added noise by the ultrasound instrument. The digital images are held in a pixel of three color components if we use RGB color model. There are several methods of image enhancement and each of them is needed for a different type of analysis. The color system used for capturing digital images in RGB, but we can make the transition from one color space to another by using conversion formulas.

$$V = \max(r, g, b) \quad (1)$$

$$S = \begin{cases} 0 & , \text{if } V = 0 \\ V - \frac{\min(r, g, b)}{V} & , \text{if } V > 0 \end{cases} \quad (2)$$

The entire Follicle Segmentation is carried out using MATLAB. Initially the patients ultrasound image (Fig 1) is to loaded as input. There are various stages in the segmentation process. The first stage is the Pre Processing which involves Cropping process (Fig 2), RGB type image conversion to Gray type conversion.

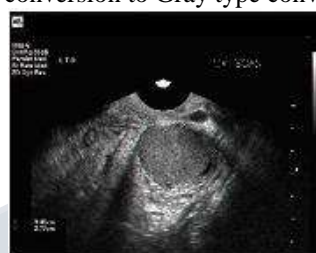

Figure 1: Input Image

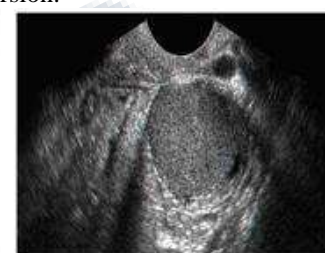

Figure 2: Cropped Image

The next stage is Layer's extraction process. RGB images have Red, Green and Blue layers. An ultrasound image of ovary shows follicles, endometrial blood vessels and stroma. The image is complicated by noise induced due to the acquisition process using the ultrasound machine. Before actual segmentation the image needs to be preprocessed to reduce false detections. In this paper we have used the CLHAE technique. The gray type image (Fig 3) is segmented separately so as the Red, Green and Blue band (Fig 4,5,6) respectively.

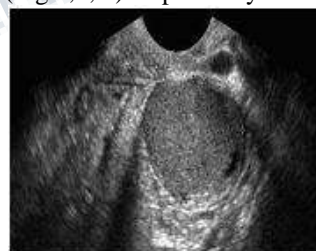

Figure 3: Gray type Image

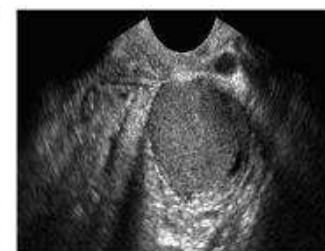

Figure 4: Red band Image

The next stage is the Enhancement Process, in this stage we are applying CLAHE Algorithm. In order to apply CLAHE algorithm three parameters needs to initialized, Intensity Threshold Value, Pixel limit lower limit level and High Threshold Value. Once initialized the size of the Gray image is Calculated. After calculating image size data type conversion takes place for an effective and noise free image enhancement. The input Ultrasound image will be enhanced as like in fig 7.



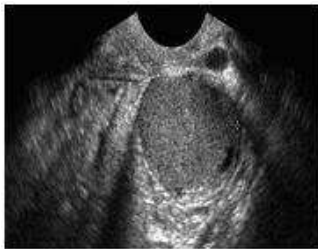


Figure 5: Green Band Image

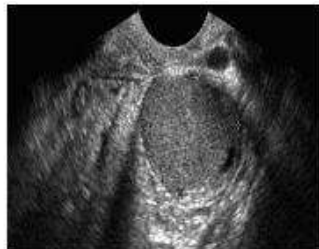


Figure 6: Blue band Image

The next stage is the Follicle Region Extraction Process. It is carried out with Weighted Median Filter. There will be some amount noise in the image. In signal processing, it is often desirable to be able to perform some kind of noise reduction on an image or signal. The median filter is a nonlinear digital filtering technique, often used to remove noise. Such noise reduction is a typical pre-processing step to improve the results of later processing (for example, edge detection on an image). Median filtering is very widely used in digital image processing because, under certain conditions, it preserves edges while removing noise. The weighted median filter is a common approach to control the importance per pixel. Instead of treating each pixel equally, the sorting function is tweaked to consider the weights. The edges of the follicle region is detected (fig 8) by using Weighted median filter.

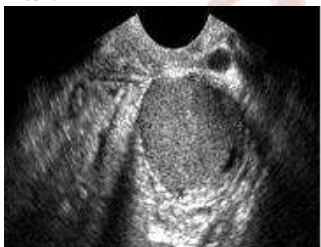

Figure 7: Enhanced Image

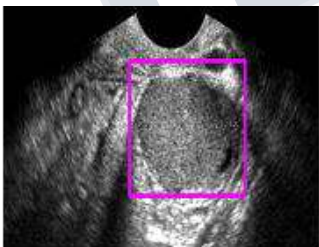


Figure 8: Edge Detection

The next stage is the Binary Operator Process. A binary operator is an operator that operates on two functions and manipulates them to return a result. Edge detection operator is a mutation in the nature of the image edge to test the edge. There are two main types: one is the first derivative-based edge detection operator to detect image edges by computing the image gradient values, such as Roberts operator, Sobel operator, Prewitt operator; the other one is the second derivative-based edge detection operator, by seeking in the second derivative zero-crossing to edge detection, such as LOG operator, Canny operator. The two functions in Binary operator process are Canny Operator and Prewitt Operator. Both the operators are edge detection operators that uses a multi-stage algorithm to detect a wide range of edges in images.

Prewitt operator edge detection masks are the one of the oldest and best understood methods of detecting edges in images. The Prewitt edge detector uses the following mask to approximate digitally the first derivatives  $G_x$  and  $G_y$ .

-1	-1	-1	-1	0	1
0	0	0	-1	0	1
1	1	1	-1	0	1
$G_x$			$G_y$		

Canny edge detection is a multistage algorithm to detect a wide range of edges in images. This detector finds edges by looking for local maxima of the gradient of  $f(x, y)$ . The gradient is calculated using the derivative of a Gaussian filter. The method uses two thresholds to detect strong and weak edges and includes the weak edges in the output only if they are connected to strong edges.

One-dimensional operator Roberts, Sobel and Prewitt are able to handle treatment effect of images of more gray-scale gradient and noise. Prewitt operator is more sensitive to horizontal and vertical edges.. The Canny operator image(Fig 9) and Prewitt operator image (Fig 10) of an follicle region is Extracted.




Figure 9: Canny operator Image



Figure 10: Prewitt operator Image

Using the Binary operators the Follicle region(Fig 11) and the Binary regions(Fig 12) are extracted. Segmentation produces homogenous regions. Each region has uniform gray-level, each region is a binary image. Binary images has more intensity values for overlapping regions. Binary images are easier to process and analyze than gray level images. The Binary Region Images analysis performs Noise suppression, Run-length encoding, Component extraction, Medial axis computation, Thinning, Feature extraction (size, orientation etc.)

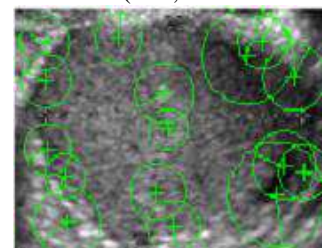


Figure 11: Follicle Region



Figure 12: Binary Region

The next stage is extraction of Follicle Location and Follicle cyst using Canny Edge process. Canny operator is based on three criteria. The basic idea uses a Gaussian function to smooth image firstly. Then the maximum value of first derivative also corresponds to the minimum of the first derivative. In other words, both points with dramatic change of gray-scale (strong edge) and points with slight change of grayscale correspond to the second derivative zero-crossing point. Thus these two thresholds are used to detect strong edges and weak edges. The fact that Canny algorithm is not susceptible to noise interference enables its ability to detect true weak edges. Canny algorithm is not susceptible to noise interference enables its ability to detect true weak edges. It's optimal edge detection algorithm. The Follicle location (Fig 13) is fused to obtain the Follicle cyst(Fig 14)




Figure 13: Follicle Location

Figure 14: Follicle cyst

**VI. RESULT AND DISCUSSION**

The proposed system has been tested on an ovarian ultrasound image to validate the accuracy of the algorithm. Figure 1 [3] shows the original ultrasound ovary image. Figure 3 [3] shows the gray scale image which is the pre processed image. Figure 4,5,6 [3] show the RGB layer extracted image. Figure 7 [3] shows the contrast enhanced image after CLAHE approach. Figure 8 [3] shows the Edge detection after Weighted median filter approach.

An image histogram is a type of histogram that acts as a graphical representation of the tonal distribution in a digital image. It plots the number of pixels for each tonal value. By looking at the histogram for a specific image a viewer will be able to judge the entire tonal distribution at a glance. The horizontal axis of the graph represents the tonal variations, while the vertical axis represents the number of pixels in that particular tone. Thus, the histogram for a very dark image will have the majority of its data points on the left side and center of the graph. Conversely, the histogram for a very bright image with few dark areas and/or shadows will have most of its data points on the right side and center of the graph.

Histogram equalization is a method in image processing of contrast adjustment using the image's histogram. This method usually increases the global contrast

of many images, especially when the usable data of the image is represented by close contrast values. Through this adjustment, the intensities can be better distributed on the histogram. This allows for areas of lower local contrast to gain a higher contrast. Histogram equalization often produces unrealistic effects in photographs; Also histogram equalization can produce undesirable effects when applied to images with low color depth. The input image histogram (Figure 15) [5] of the ultrasound ovary image is obtained and also the Filtered Image Histogram (Figure 16) [5] is obtained. The Binary process is carried out and the Canny operator Image (Fig 9) [4] and Prewitt operator image (Fig 10) [4] are extracted. Once these region are extracted the follicle surface is identified and the follicle region (Fig 11) [4] is extracted. Then by binary conversion process the binary region(Fig 12) [4] is extracted. By canny edge process the Follicle location (Fig 13) [4] is extracted and that is further fused to obtain follicle cyst (Fig 14) [4].

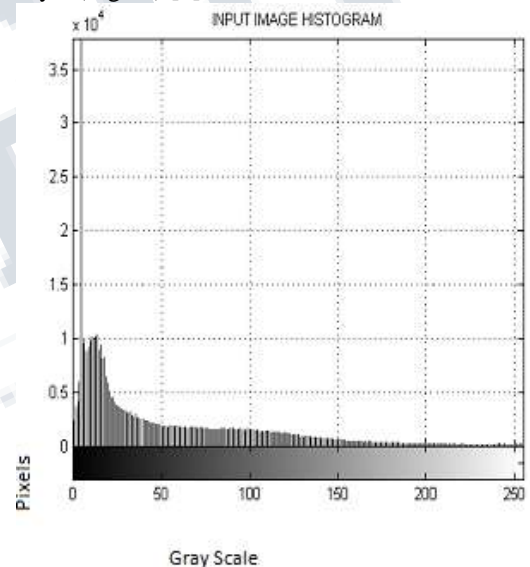


Figure 15: Input Image Histogram

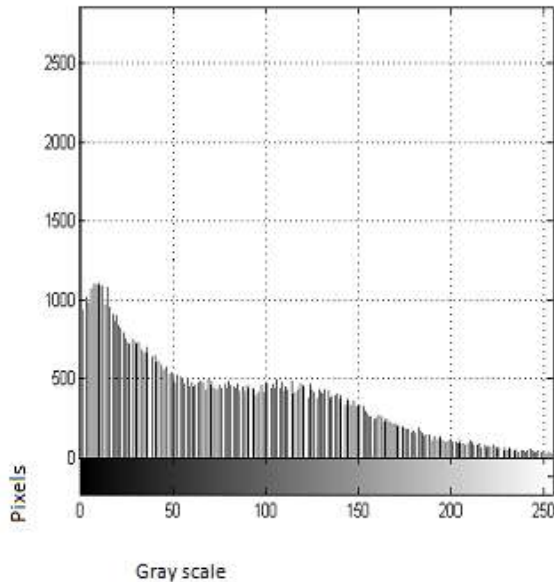


Figure 16: Filtered Image Histogram.

Thus after segmenting and extracting all the images from the original ultrasound image a Confusion matrix is plotted with the obtained segmented images using MATLAB. A confusion matrix is a table that is often used to describe the performance of a classification model on a set of test data for which the true values are known.

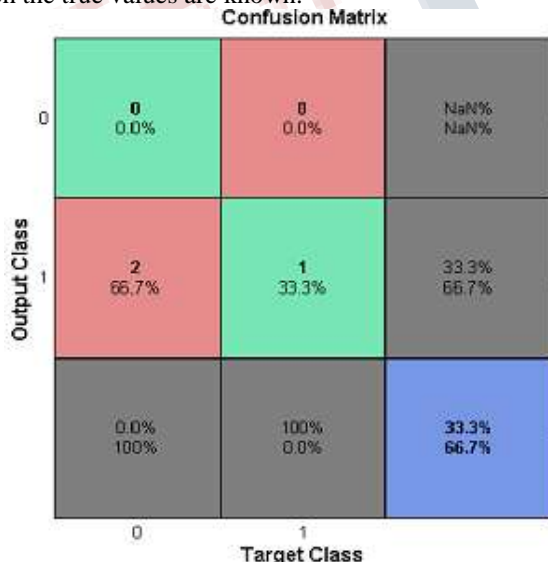


Figure 17: Confusion Matrix

In the above confusion matrix the column (0,0) represents the True Positive. The Recall or True Positive(TP) is the proportion of positive cases that were correctly identified, as calculated using the equation:

$$TP = \frac{d}{c+d}$$

The column (0,1) represents the False Positive. The False Positive Rate (FP) is the proportion of negatives cases that were incorrectly classified as positive, as calculated using the equation:

$$FP = \frac{b}{a+b}$$

The column (0,2) represents Positive Prediction which could not be predicted so the outcome will be (NaN) Not a Number. Positive Predictive value is the probability that subjects with a positive screening test truly have the disease.

$$FN = \frac{c}{c+d}$$

The column (1,0) represents False Negative. The False Negative Rate (FN) is the proportion of Positive cases that were incorrectly classified as negative, as calculated using the equation:

$$TN = \frac{a}{a+b}$$

The column (1,1) represents True Negative. The True Negative Rate (TN) is defined as the proportion of negatives cases that were classified correctly, as calculated using the equation:

$$AC = \frac{a+d}{a+b+c+d}$$

The column (1,2) represents Negative Prediction. Negative Predictive Value is the probability that subjects with a negative screening test truly don't have the disease.

The column (2,0) represents Eccentricity. The column (2,1) represents the specificity. And the column (2,2) represents the Accuracy. The Accuracy is the proportion of the total number of predictions that were correct. It is determined using the equation:

Thus with the help of the above results and manual result the diagonising is made much easier and the presence of PCOS is also identified and also their signal to noise ratio (SNR) and Peak signal to noise ratio is also calculate (PSNR).

## VII. CONCLUSION

In this paper, segmentation of ovarian follicle in ultrasound image has been addressed. With use of Contrast Limited Adaptive Histogram Equalization (CLAHE) it enhances the contrast and suppresses the noise present in the ultrasound image. Then the Weighted median filter and Histogram Equalization are used for the segmentation and improved contrast of enhanced image. As a fundamental



development automated classification of normal and polycystic ovary syndrome patients can be done.

Hence the developed methodology yields acceptable results for the sample images considered when compared with manual segmentation. This will provide a helping hand to the experts to reduce the burden of manual selection of follicles from the image. This algorithm can be deployed for the mass screening of the patients at an early stage.

### REFERENCES

- [1] Palak Mehrotra , Chandan Chakraborty, Biswanath Ghoshdastidar, Sudarshan Ghoshdastidar, Kakoli Ghoshdastidar," Automated Ovarian Follicle Recognition for Polycystic Ovary Syndrome," 2011 International Conference on Image Information Processing (ICIIP 2011).
- [2] M. J. Lawrence, R.A.Pierson , M.G.Eramian, E. Neufeld, " Computer assisted detection of polycystic ovary morphology in ultrasound images," In Proc. IEEE Fourth canadian conference on computer and robot vision (CRV'07) , pp. 105-112 , 2007.
- [3] U. Bako, S. Morad, and W. A. Atiomo," Polycystic ovary syndrome: An overview. Reviews in Gynaecological practice," 5(2):115–122, 2005.
- [4] H. Balen, J. S. E. Laven, S.-L. Tan, and D. Dewailly," Ultrasound assessment of the polycystic ovary: international consensus definitions," Human Reproduction Update,9(6):505–514, 2003.
- [5] Yin-hui Deng , Yuanyuan Wang, Yuzhong Shen , "An automated diagnostic system of polycystic ovary syndrome based on object growing," Artificial Intelligence in Medicine, vol. 51, pp. 199-209 ,2011.
- [6] Affiliates of Medifocus.com," Medifocus guidebook: polycystic ovary syndrome," Silver Spring: Medifocus.com, Inc.; 2007.
- [7] Loizou CP, Pattichis CS, Christodoulou CI, Istepanian RSH, Pantziaris M, Nicolaidis A," Comparative evaluation of despeckle filtering in ultrasound imaging of the carotid artery," IEEE Transactions on Ultrasonics, Ferroelectrics and Frequency Control 2005;52:1653–69.
- [8] B.Potocnik, D.Zazula, "The XUltra project- Automated Analysis of Ovarian ultrasound images," Proceedings of the 15th IEEE symposium on computer based medical systems (CBMS'02).
- [9] B. Cigale, D. Zazula, "Segmentation of ovarian ultrasound images using cellular neural networks," Proceedings of 7th International workshop on systems, signals and image processing, Maribor, Slovenia, 2000, pp. 33-36.
- [10] Maribor, Slovenia, 2000, pp. 33-36. Krivanek, M. Sonka, "Ovarian ultrasound image analysis: Follicle segmentation," IEEE Transaction on medical imaging, vol. 17, no.6, 1998, pp. 935-944.
- [11] Anthony krivanek and milan sonka, "ovarian ultrasound image analysis: follicle segmentation," IEEE Transactions on medical imaging, vol. 17, no. 6, december 1998.
- [12] M. Taneja, G. Singh, S. M. Totey, and A. Ali, "Follicular dynamics in water buffalo superovulated in presence or absence of a dominant follicle," *Theriogenol.*, vol. 44, pp. 581–597, 1995.
- [13] K. H. Kaulfuss, S. Brabant, K. Blume, and J. May, "The improvement of embryo transfer programmes by examination of the ovary response in superovulated donor ewes by transrectal real-time ultrasound," *Deutsche Tieraerztliche Wochenschrift*, vol. 102, pp. 208–212, 1995.
- [14] P.S.Hiremath and Jyothi.R.Tegnoor, "Automatic detection of follicles in Ultrasound images of ovaries," Proc. 2nd International conference on Cognition and Recognition – ICCR08(India, Mysore),pp. 468-473.
- [15] Sarty G E, Liang W, Sonka M and Pierson R, " A Semiautomated segmentation of ovarian follicular ultrasound images using a knowledge based algorithm," Ultrasound in medicine and biology, vol 24, no 1, 1998,pp 27-42.
- [16] R.C.Gonzalez , R.C.Woods, Digital Image Processing , 3rd Edition,Pearson Education, New Delhi , 2009.
- [17] P.S.Hiremath and J.R.Tegnoor , " Recognition of follicle in ultrasound images of ovaries using geometric features," Biomedical and Pharmaceutical Engineering ( ICBPE '09), pp. 1-5, 2009.
- [18] Affiliates of Medifocus.com, "Medifocus Guidebook: Polycystic Ovary Syndrome," Medifocus.com, Inc, 2007.

**International Journal of Science, Engineering and Management (IJSEM)**  
**Vol 1, Issue 5, September 2016**

---

- [19] S.Frank Medical Progress:Polycystic Ovary Syndrome. New England Journal of Medicine, 333(13), pp.853-861, 1995.
- [20] Roy Homburg, "Management of polycystic ovary syndrome in adolescence," Reviews in Gynaecological Practice, vol. 4 , pp. 148–155, 2004.
- [21] Eldon Schriock, Mary C. Martin, Robert B. Jaffe,"Polycystic Ovarian Disease \*Medical Progress+,"Western Journal of Medicine, vol. 142(4), pp.519-522, 1985.
- [22] A.H.Balen, J.S.E.Laven, S-L.Tan, D.Dewailly,"Ultrasound assessment of the polycystic ovary : international consensus defination," Human Reproductive Update, vol. 9(6), pp. 505-514 , 2003.
- [23] M. J. Lawrence, R.A.Pierson , M.G.Eramian, E. Neufeld, " Computer assisted detection of polycystic ovary morphology in ultrasound images," In Proc. IEEE Fourth canadian conference on computer and robot vision (CRV'07) , pp. 105-112 , 2007.
- [24] S. Burrell and A. MacDonald, "Artifacts And Pitfalls in Myocardial Perfusion Imaging," *Journal of Nuclear Medicine Technology*, Vol. 34, No. 4, 2006, pp. 193-211.
- [25] C. X. Wang, L. Small, W. E. Snyder and R. Williams, "Edge Detection in Gated Cardiac Nuclear Medicine Images," *IEEE 7th Symposium on Computer Based Medical Systems*, Winston-Salem, 10-12 June 1994, pp. 28-33.
- [26] E. D. Pisano, S. Zong, B. M. Hemminger, M. DeLuca, R.
- [27] E. Johnston, K. Muller, M. P. Braeuning and S. M. Pizer, "Contrast Limited Adaptive Histogram Equalization Im-age Processing to Improve the Detection of Simulated Spiculations in Dense Mammograms," *Journal of Digit Imaging*, Vol. 11, No. 4, 1998, pp. 193 -200.
- [28] R. Garg, B. Mittal and S. Garg, "Histogram Equalization Techniques for Image Enhancement," *International Jour-nal of Electronics and Communication Technology*, Vol. 2, No. 1, 2011, pp. 107-111.
- [29] S. Srinivasan and N. Balram, "Adaptive Contrast Enhancement Using Local Region Stretching," *Proceedings of ASID '06*, New Delhi, 8-12 October 2006, pp. 152-155.
- [30] S. K. Shome and S. R. K. Vadali, "Enhancement of Diabetic Retinopathy Imagery Using Contrast Limited Adaptive Histogram Equalization," *International Journal of Computer Science and Information Technologies*, Vol. 2, No. 6, 2011, pp. 2694-2699.
- [31] J. A Stark, "Adaptive Image Contarst Enhancement Using Generalizations of Histogram Equalization," *IEEE Transactions on Image Processing*, Vol. 9, No. 5, 2000, pp. 889-894.
- [32] M. T. Madsen, "Recent Advances in Spect Imaging," *The Journal of Nuclear Medicine*, Vol. 48, No. 4, 2007, pp. 661-673.